

Direct and Indirect Restoration of Deformed Teeth for a Patient with Molar-Incisor-Hypoplasia: A Case Report

Omar M. Mesrabi ^{1*}, Nourjahan M. Haitham ²

ARTICLE INFO.

Keywords:

Molar, Incisor, Hypoplasia, Restoration, Esthetics, Implants.

Abstract

Background: molar incisor hypoplasia is a rare condition affecting the permanent first molars and anterior teeth compromising function and esthetics. Purpose: this case report was done to discuss the proper treatment for MIH patients with crowns and composite veneers to restore the missing tooth structure, lack of function & poor esthetics.

Methods: patient came to outpatient clinic suffering from low self-confidence and inability to chew food. Upon examination and investigations, she was diagnosed with MIH where her anterior teeth and first molars in both maxilla and mandible were affected.

Conclusions: A detailed treatment plan was made starting with periodontal therapy followed by full ceramic crowns in upper anterior teeth, direct veneers in lowers followed by endodontic treatment in the molars and implants in the missing lower left molar and a bridge on the lower right side. The chosen treatment plan yielded great results and restored both the function and esthetics of the patient.

© 2023 MSA. All rights reserved.

1. Introduction

Molar-incisor hypoplasia (MIH) is a very rare condition in which the permanent first molars and anterior teeth are affected by lack of calcification in the tooth structure leading to badly mutilated teeth with impaired function and esthetics. Epidemiological studies from different parts of the world show a wide variation in the prevalence of MIH which can range between 2.8 to 40.2%.¹

Bonding to hypomineralized MIH enamel is the controlling factor in adhesion of the planned restorations.² Another study showed that routine bonding of resin-based composite to hypoplastic or hypocalcified enamel using the acid-etch method is not predictable or reliable over the long term and debonding is often seen from the tooth structure because of its weakened state.³

* Corresponding author.

E-mail address: omarmis1998@outlook.com

¹ Intern, Faculty of Dentistry, October University for Modern Sciences and Arts

² Teaching Assistant of Oral Medicine, Faculty of Dentistry, October University for Modern Sciences and Arts

Accordingly, full coverage crowns were placed in upper anterior teeth and direct composite veneers in lower anterior teeth as upon examination the severity of pitting in the upper teeth was greater than the lower.

The use of implants showed markedly better results than conventional bridges to restore missing teeth; due to the preservation of both bone and adjacent abutments. In addition, it improved periodontal health and allowed proper oral hygiene measures to be carried out.

2. Case presentation:

This case report has been described according to the 2013 CARE checklist for case report writing and publishing guidelines.

2.1 Patient Information:

A 22-year-old female patient came to MSA university clinics complaining about her unpleasant smile and inability to chew food properly with food accumulation in missing teeth areas. A proper medical history was taken and it was found that she suffered from severe fever at a young age which affected her teeth including maxillary and mandibular anteriors and first molars. She also suffered from iron deficiency anemia and GIT problems due to incompetent chewing of food. Upon taking dental history, failed extraction of lower first permanent molars was present leaving retained roots on both sides. In addition, a defective composite restoration was placed in tooth number 21.

2.2 Clinical Findings:

Clinical examinations showed multiple hypoplastic and carious lesions varying in size and depth from tooth number 13 to 23 & from 33 to 43. (Figure 1)

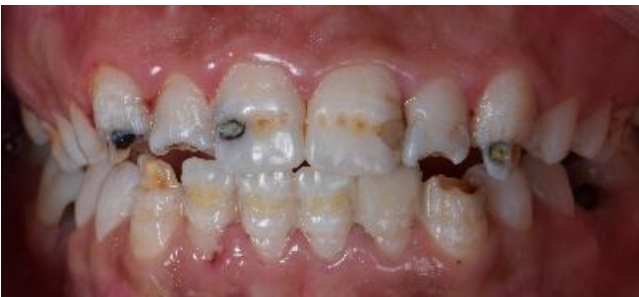

Figure 1. carious lesions in 13 to 23& 33 to 43

Posteriorly, badly decayed 16 & 26, and retained roots in 36 & 46 were found. (Figures 2&3)

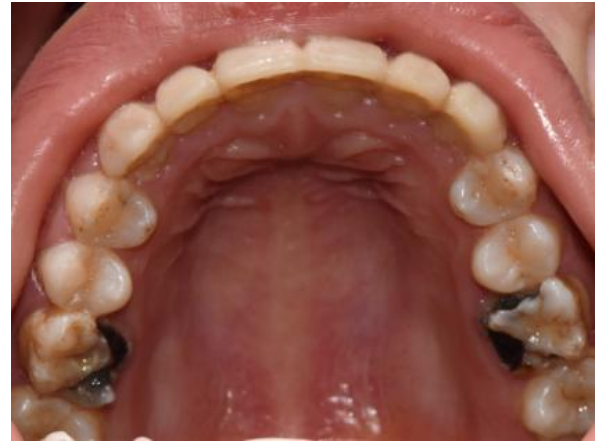

Figure 2. badly decayed 16 & 26

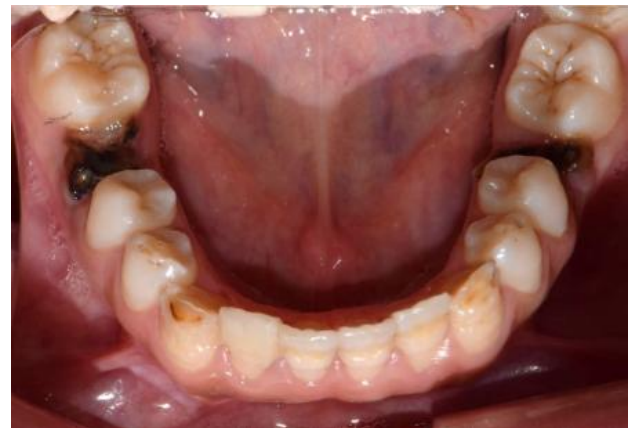

Figure 3. retained roots in 36 & 46

The hypoplastic lesions resulted from a severe fever she suffered at young age according to her medical history. Moreover, the gingiva was mildly edematous and showed signs of inflammation caused by her inadequate oral hygiene. Upon periodontal examination, mild marginal gingivitis was found with localized periodontitis at teeth number 16 & 26 where the probing depth was increased up to 3.5mm due to lack of proper oral hygiene and hypofunction at these areas. Preoperative intraoral photographs were recorded from different aspects using Nikon D5100 DSLR camera.

2.3 Diagnostic assessment:

Visual examination, radiographs and complete blood count test (CBC) were taken to confirm diagnosis. A panoramic x-ray assisted in evaluation of the oral hard tissues and showed the remaining roots. (Figure 4)

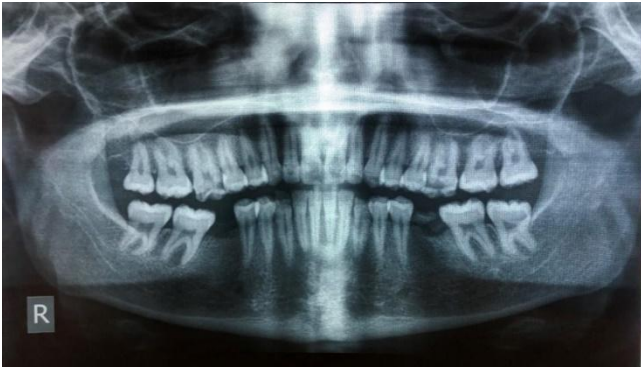

Figure 4. panoramic x-ray showing remaining roots.

Regarding the lower left molar area, cone beam CT was requested to show the depth, width and quality of the bone and the surrounding vital structures for an implant placement surgery of tooth number 36. (Figure 5)

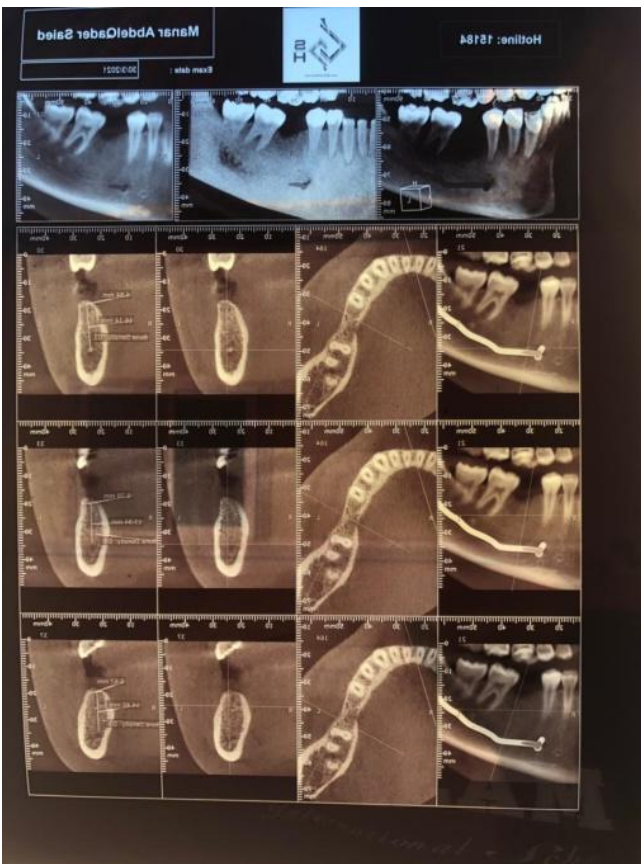


Figure 5. cone beam CT showing depth, width and quality of bone.

Many challenges were raised including impaired function with inability to chew food, accumulation of food in missing teeth areas, plaque induced gingivitis, multiple carious and hypoplastic lesions and finally low economic status of the patient. However, esthetics was the most important challenge as it was the patient's chief complaint. Overall, the patient's oral state was favoring a good prognosis as sufficient tooth structure was present in addition to her

motivation in this young age.

2.4 Therapeutic Intervention:

Firstly, periodontal therapy was performed. Scaling and root planning were done to reinforce the gingival health and improve the oral hygiene. Diagnostic wax-up and a motivational mockup were fabricated as a simulation of the final result and motivation of the patient (Figures 7, 8 & 9).

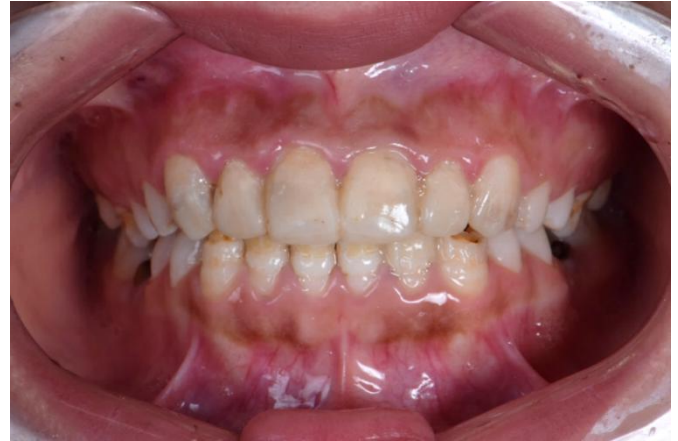

Figure 7. diagnostic wax up frontal view.

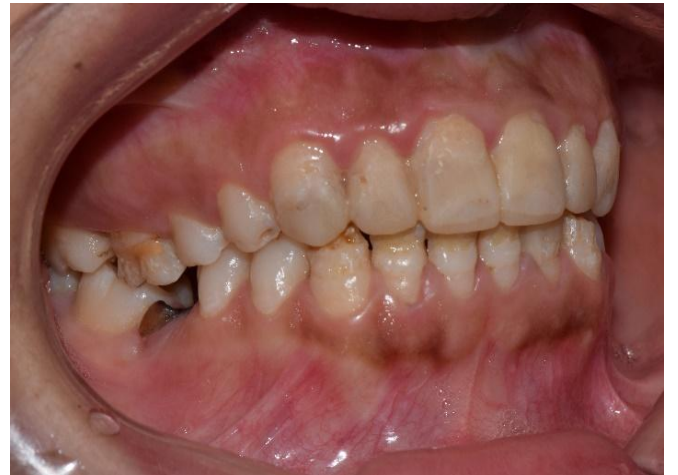

Figure 8. diagnostic wax up right sideview.

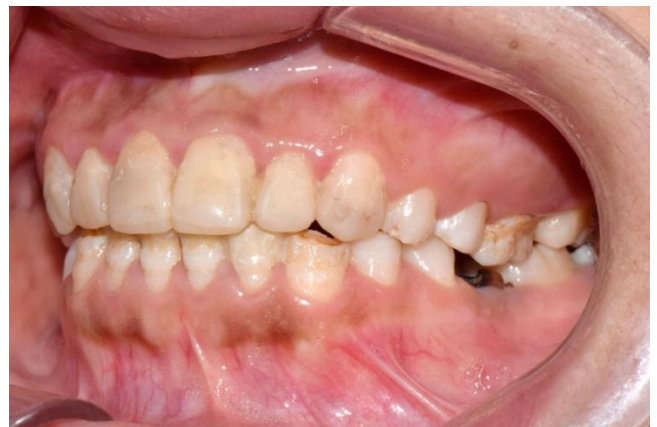

Figure 9. diagnostic wax up left side view.

The mandibular remaining roots in the molar area were removed atraumatically. A restorative treatment was then carried out to remove the carious lesions and E-max crowns were placed on the maxillary anterior teeth (Figures 10-12).

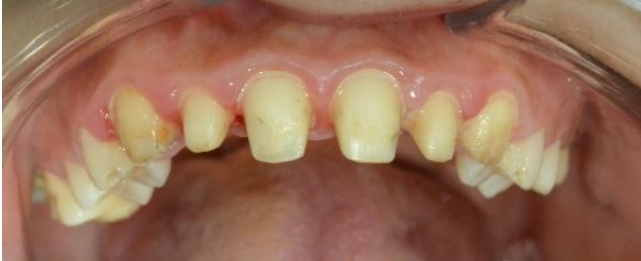

Figure 10. crown preparation for maxillary anterior teeth.

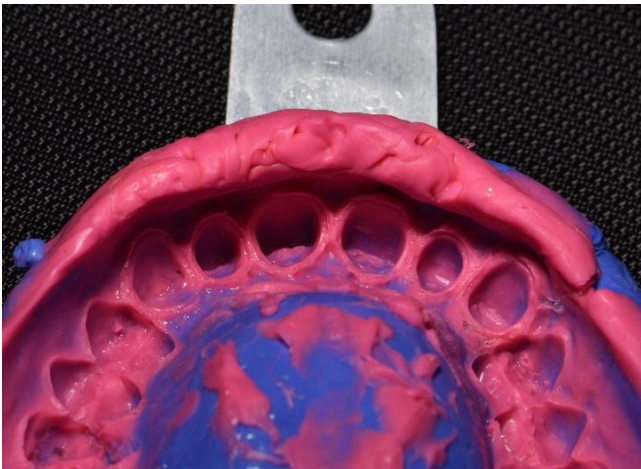

Figure 11. Final impression of prepared maxillary anterior teeth.

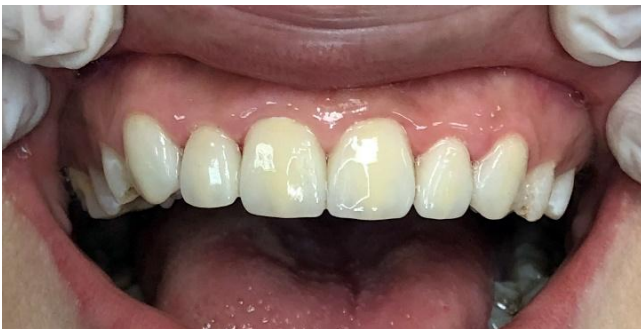

Figure 12. E-max crowns of maxillary anterior teeth.

Furthermore, endodontic treatment was done for teeth number 16 & 26 followed by post and core followed by E-max crowns as well (Figures 13 & 14).

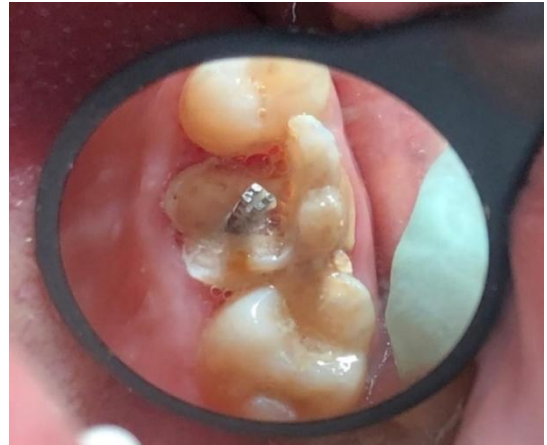

Figure 13. post placement for tooth number 26

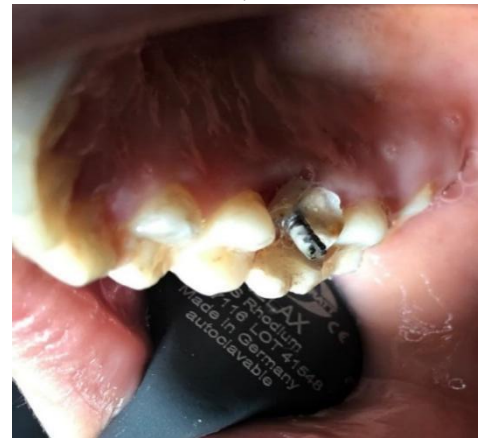

Figure 14. post placement for tooth number 16.

Regarding the lower anterior teeth, direct composite veneers was the plan of choice as a conservative treatment (Fig. 15 & 16).

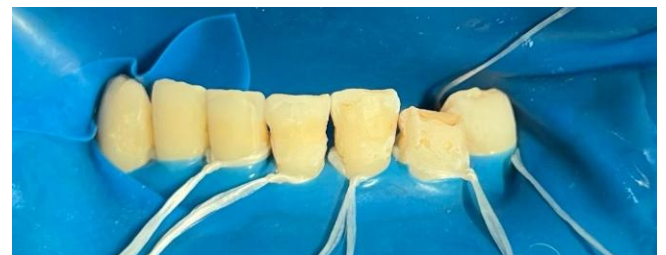

Figure 15. rubber dam placement for lower anterior teeth.

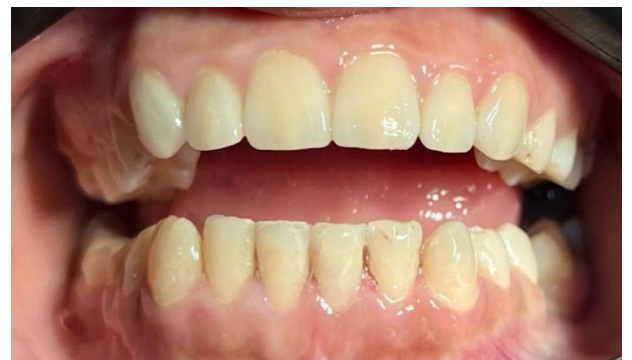

Figure 16. final composite restoration for lower anterior teeth.

Type of restoration was guided by amount of tooth structure and amount of available enamel for proper bonding as for teeth that lack most of their enamel, direct or indirect veneers may not bond properly; therefore, full coverage is preferable.⁴

Additionally, a zirconium bridge preparation was done to restore the missing tooth number 46 (Figure 17) and a titanium implant was placed also to restore tooth number 36. This treatment was chosen according to amount of bone as one of the key requirements for dental implant treatment is having enough bone, which is a solid reliable base to anchor the implant.⁵ This was found in the left area and a successful dental implant was placed (Figures 18-21).

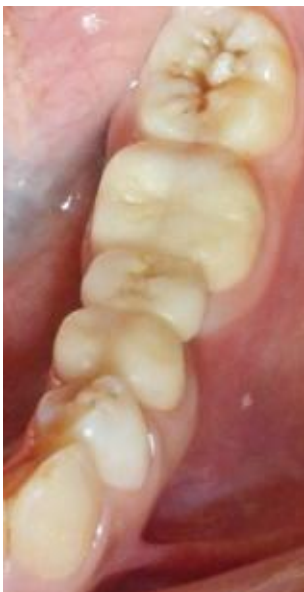

Figure 17. zirconium bridge preparation to restore tooth 46.

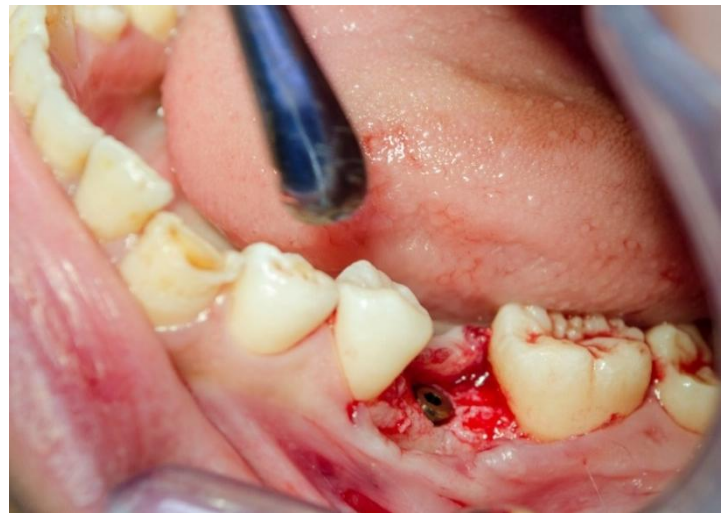

Figure 19. placement of implant.

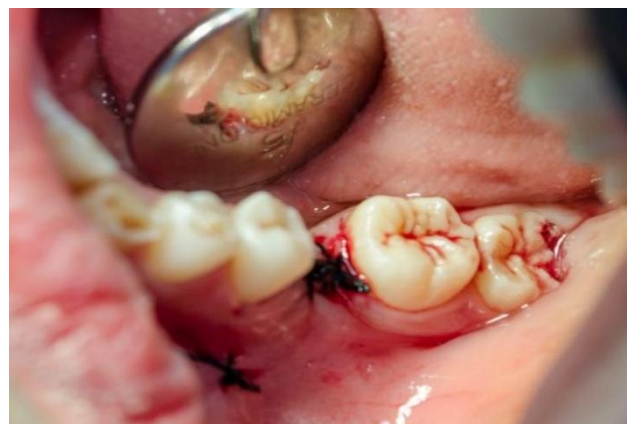

Figure 20. closing the wound by sutures.

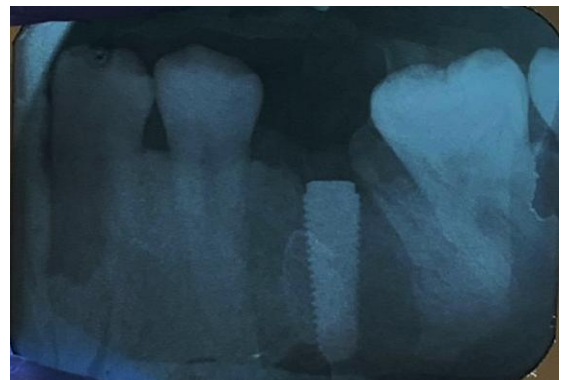

Figure 21. x-ray image showing the implant after placement.

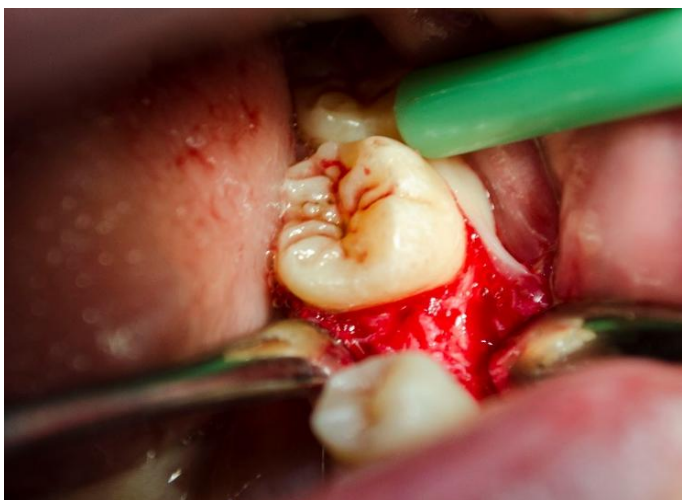

Figure 18. flap preparation for implant placement.

After 3 months follow up, osseointegration was successfully achieved and the implant was ready to be loaded. Thereby, a premolar-shaped zirconia crown was placed as the space was insufficient to restore a molar-shaped abutment. This was achieved by a closed tray impression technique to transfer the implant-abutment relation to the dental lab (Figures 22-26).

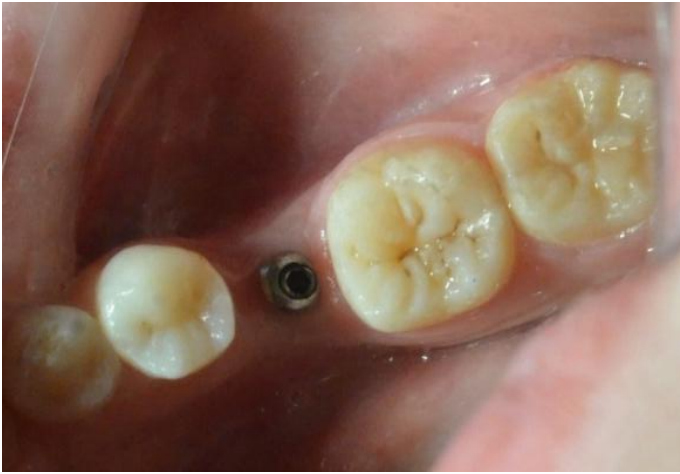

Figure 22. implant after 3-month osteointegration.

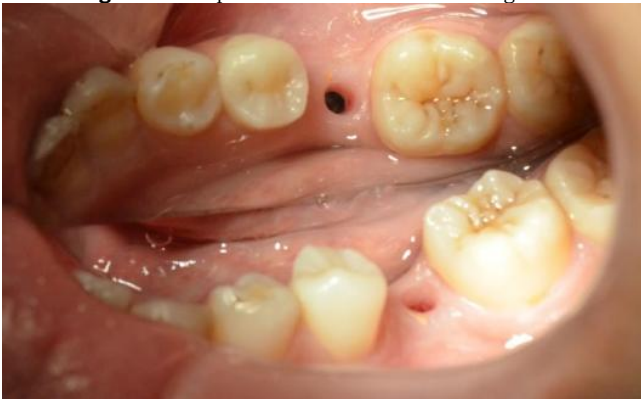

Figure 23. removal of the abutment to prepare for impression.

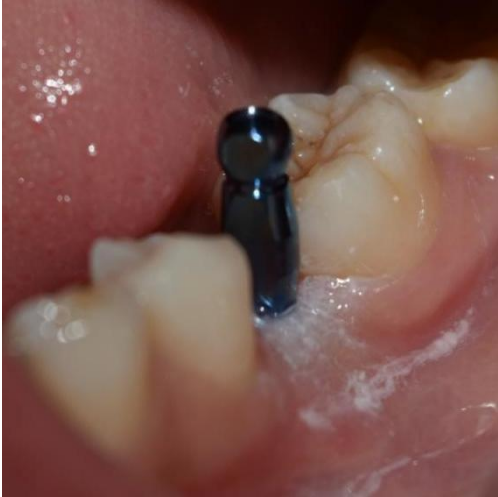

Figure 24. preparing the implant for closed tray impression.

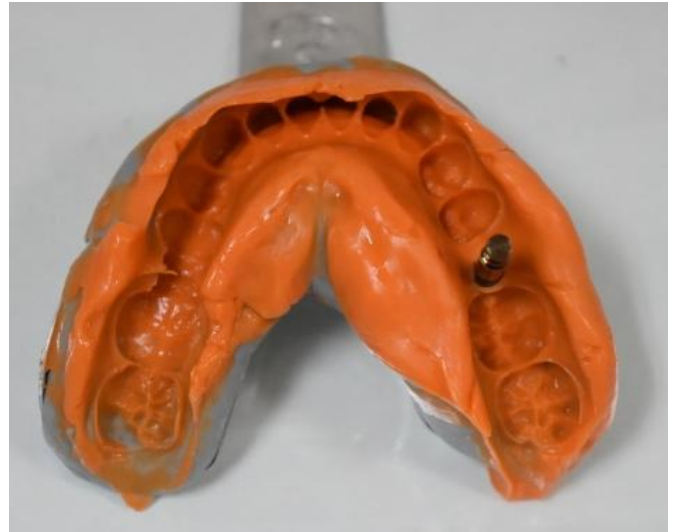

Figure 25. closed tray impression.

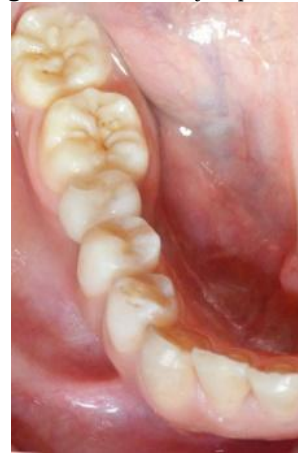

Figure 26. placement of the restored crown for tooth 36.

On the contrary, the lower right molar area had insufficient bone volume which prevented the placement of a dental implant and hence a zirconium bridge was placed⁵. Alongside the dental intervention, the patient was instructed to follow a calcium rich diet in addition to iron injection for treating severe anemia. A three month follow up to monitor the restorations and the prosthesis was advised.

3. Follow up and outcomes:

The patient was recalled to MSA university clinics after 4 months for checking the integrity of the fixed prosthesis and assessing the oral hygiene. The gingival health was greatly improved as the patient followed strict oral hygiene measures such as using soft dental brush, dental flossing and using mouthwash. Mild stains were found on the palatal surface of the maxillary anterior teeth which were removed with polishing.

4. Discussion:

Enamel hypoplasia can cause partial or complete loss of enamel that may be systemic (affecting

multiple teeth) or local (affecting single tooth).⁶ According to a study, its prevalence ranges between 2.5% and 40%. This case had systemic type which affected both upper and lower anterior teeth.

The choice of placing the maxillary anterior crowns was due to presence of insufficient tooth structure after caries removal which made it the best treatment option. As the hypoplasia was severely affecting the upper teeth, bonding of veneers would have shown a bad prognosis. According to many studies, higher cohesive failures were shown in hypomineralized enamel -whatever the adhesive used- compared to bonding to sound enamel.⁷

On the other hand, the lower anterior teeth were covered by direct veneers due to adequate tooth structure which favored bonding of composite. So, a "non-invasive treatment" with the removal of affected enamel only was carried out. This showed success rates in many studies too.^{8,9}

Regarding the mandibular posterior areas, the bridge placed in the right side was the ideal treatment. Upon investigations, insufficient space was found between the abutments which lead to fewer complications like damage to adjacent periodontal ligament, loss of implant due to infection or bone resorption, and loss of tooth as the adjacent tooth may be irreversibly traumatized and may be lost to a fracture or to internal or external resorption.

Luckily sufficient bone and space were present on the opposite side which favored an implant placement as the first choice. A flap was raised, and a 14 mm implant was placed with respect to the vital structure (IAN) by keeping two mm distance between them.⁸ Afterwards, a closed tray impression was taken and the implant was then loaded by a zirconium crown.¹⁰

5. Patient perspective:

The patient was so satisfied with the treatment outcome. Her esthetics were markedly improved which made her regain self-confidence. Her GIT problems were reduced due to proper mastication of food. Finally, her psycho-social health was improved.

6. Conclusion:

MIH is a rare condition that requires properly and fully detailed medical history to confirm diagnosis. Presence of adequate tooth structure guides the choice of the final restorations. Gingival health is crucial for the long-term success of the fixed prosthesis and implants.

Informed consent:

The patient signed the consent approving all the procedures and sharing this article with the attached images.

Conflict of interest

The authors declare that they hold no competing interests.

Funding

The research study was self-funded by the authors.

Acknowledgement

The authors would like to thank Asst.Prof. Dr. Samy Mounir, Dr Ruba Eldamarisy, Dr. Amr Aziz, Dr. Mohamed Abouheikal, Dr. Ahmed Wagdy and Asst Prof. Dr. Dina Elawady for their efforts in supervising this work. The authors would also like to thank Mary Amir Khalil, Mariam Raouf Ramzi, Mariam Samir Hamada for their efforts in the clinical work.

6. References

- [1] Ghanim A, Silva MJ, Elfrink MEC, Lygidakis NA, Mariño RJ, Weerheijm KL, Manton DJ. Molar incisor hypomineralisation (MIH) training manual for clinical field surveys and practice. *Eur Arch Paediatr Dent*. 2017 Aug;18(4):225-242. doi: 10.1007/s40368-017-0293-9. Epub 2017 Jul 18. PMID: 28721667.
- [2] Krämer N, Bui Khac NN, Lückner S, Stachniss V, Frankenberger R. Bonding strategies for MIH-affected enamel and dentin. *Dent Mater*. 2018 Feb;34(2):331-340. doi: 10.1016/j.dental.2017.11.015.
- [3] T.P. Croll Treatment Options for Hypoplastic and Hypocalcified Permanent Molars in Children *Inside Dentistry*, August 2014, Volume 10, Issue 8.
- [4] T. Broderick What Are the Treatments for Enamel Hypoplasia? *Wisegeek*, May 07, 2022.
- [5] C. Neil Have I got enough bone for teeth implants? *Confident Dental Implants*, Stroud. Feb. 2017.
- [6] N. Mittal, V. Parashar Aesthetic management of enamel hypoplasia in maxillary lateral incisor with prefabricated composite veneer. *Annals of Prosthodontics and Restorative Dentistry*, October-December, 2015;1(1):54-57.
- [7] Lee, YL., Li, K.C., Yiu, C.K.Y. et al. Evaluation of developmentally hypomineralised enamel after surface pretreatment with Papacarie Duo gel and different etching modes: an in vitro SEM and AFM study. *Eur Arch Paediatr Dent* 23, 117–131 (2022).
- [8] Almaz Me, Oba Ma, Sonmez IS. Sanmea D Comparison of shear bond strengt of selkadherring towable composite win diferent Towable composites to dentin *Eut J Gen Dent* 2016:516-10
- [9] M. Lagarde, E. Vennat, J.Attal, E.Dursun. Strategies to optimize bonding of adhesive materials to molar-incisor hypomineralization-affected enamel: A systematic review. *International Journal of Paediatric Dentistry*, Wiley, 2020.
- [10] Juodzbalys G, Wang HL, Sabalys G. Injury of the Inferior Alveolar Nerve during Implant Placement: a Literature Review. *J Oral Maxillofac Res*. 2011;2(1):e1. Published 2011 Apr 1. doi:10.5037/jomr.2011.2101